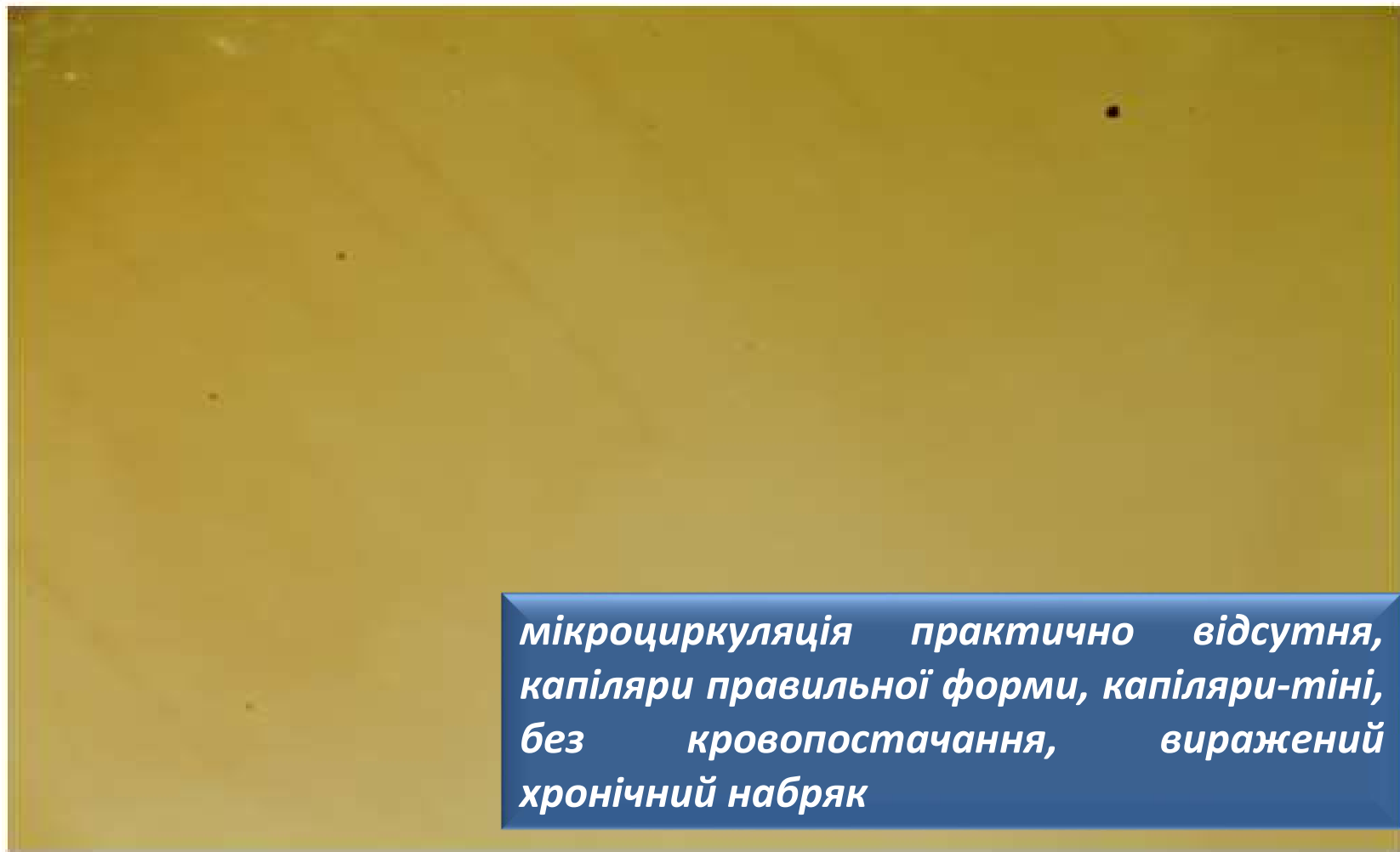

Пацієнт: Haroon Al Maskari

Діагноз: більшість лікарень ставили діагноз як генетична хвороба. Ми вирішили лікувати цю хворобу як апалічний синдром, оскільки пацієнт мав схожі скарги.

***1-й день лікування
результат технології судинного скринінгу***

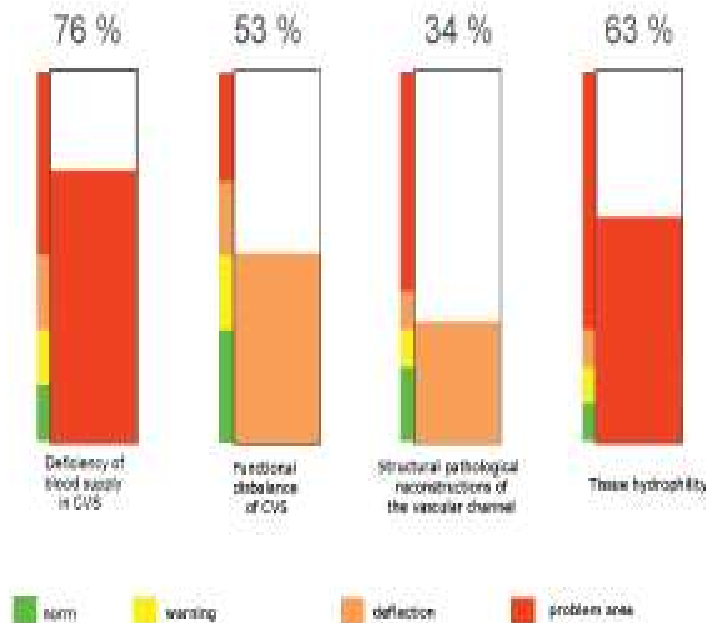


***мікроциркуляція практично відсутня,
капіляри правильної форми, капіляри-тіні,
без кровопостачання, виражений
хронічний набряк***

VASCULAR SCREENING TECHNOLOGY

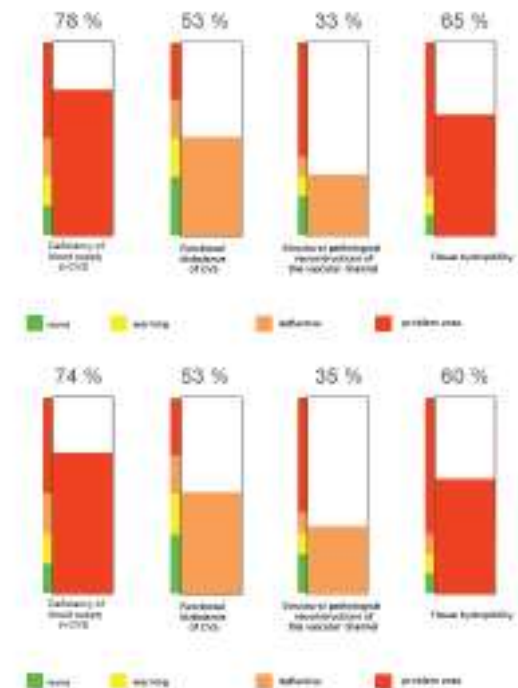
Date of check-up: 05.09.2016, 08:09	Name of a patient: Haroon Al Maskari	Date of birth of a patient: 01.01.2009
Medical card: 18	Full age: 7	Examined by: Omwuka Obinna

Загальна гісторграма судинного скринінгу, сформована на основі кількох зображень



Attention! When at least one parameter is in a red range - it is necessary immediately to start the course of vascular treatment - angiotherapy.

the ring-finger of the left hand



Conclusions of the screening of the individual adequacy of blood supply for the organism by the cardiovascular system

Alerting critical level of blood supply and tissue edema on the background of the subcritical disturbance level of structure and function of the vascular bed. The high degree of imbalance of the cardiovascular system by the chaos 2-3 type.

Possible risks and condition of reserves the vascular system

High risk of critical and terminal states! Autocompensation reserves are significantly reduced. High risk of structural rearrangements in micro- and peripheral vessels of various origins (it is necessary to differentiate angiodystonia, endocrinopathy, pathological angiogenesis, increased blood clots, etc.).

Necessary additional examinations of the cardiovascular system

Recommended detailed examination of microvessels with expanded vascular screening program - Angiomarkers and detailed examination of the cardiovascular system. Recommended further examinations of hormonal mirror of the sexual sphere.

Recommendations in relation to the removal of the problem

Attention! When at least one of the parameters is in the red range, the treatment should be started immediately. Recommended urgent angiotherapy (personalized vascular treatment) to correct the cardiovascular system. Compensation reserves of the cardiovascular system are practically absent. The treatment process is recommended to perform only with angiomarker monitoring (innovative technology for integrated vascular diagnostics) as the personalized evidence-based treatment. The purpose of such

1-й день лікування Результат електрокардіограми серця

Значні розлади обміну речовин і кровообігу в кровопостачанні серця.

В нормі портрет серця має бути повністю зеленого кольору.

ZDEX - Harron AL Maskari, 6 years

View and Print a report

Into patient chart | Simple | General | **Expert** | HeartVue | ECG | Print

Expert's annotation

Analysis of microalterations HeartVue™ on ECG record 30 sec.

Time, s	Myocardium,%	Func. reserve, %	Rhythm,%	Pulse, beats / min	G1- G2- G3- G4- G5- G6- G7- G8- G9	T-alter., μV	Index of electrical instability
00:00 - 00:30	18	84	69	110	3 - 2 - 2 - S - 1 - 1 - 2 - S - 12	20	1

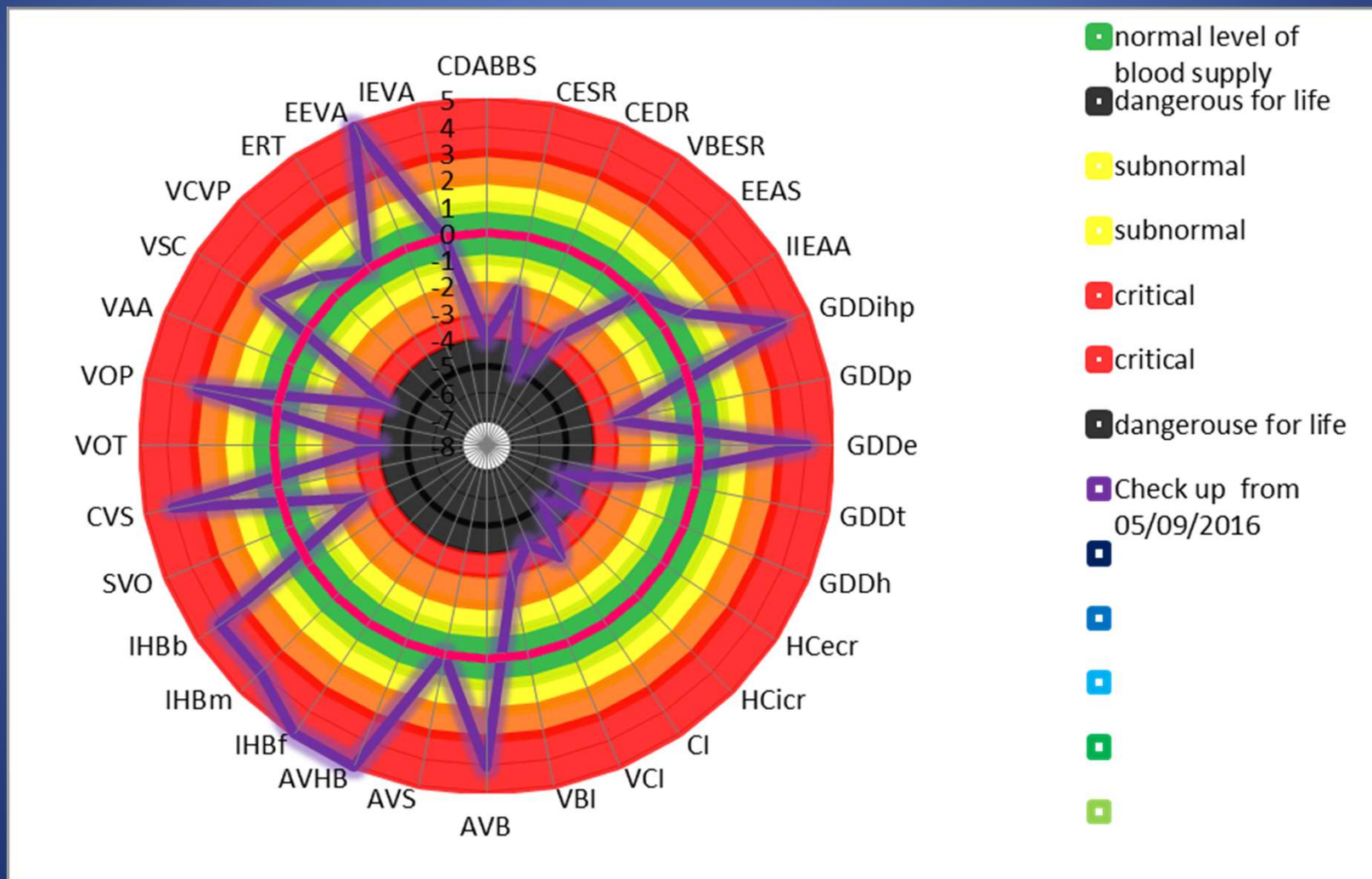
GENERAL CONCLUSION

18%: If these deviations are observed first time and are repeated on sequential heart porterts, you should control the dynamics of examinations. Significant DISPERSIVE DEVIATIONS from norm. Moderate changes in process of atriums denervation.

RU 12:39 16.09.2016

1-й день лікування

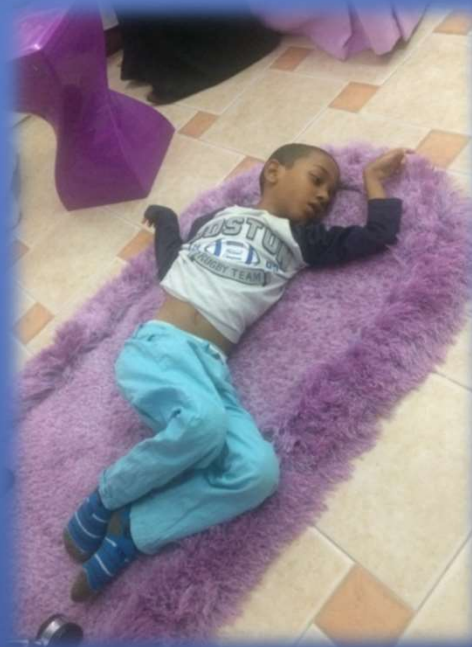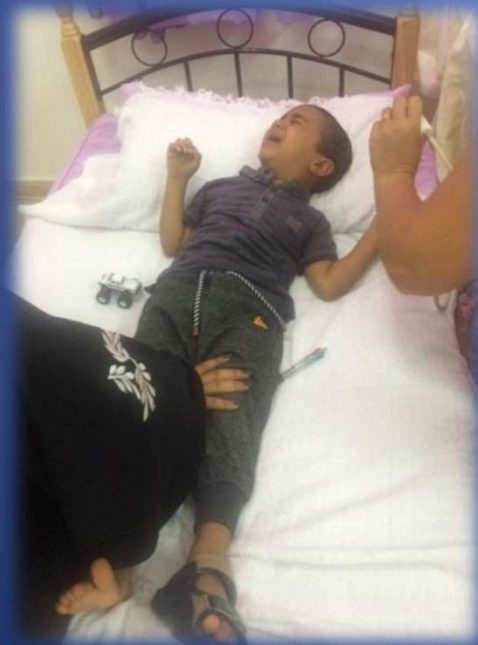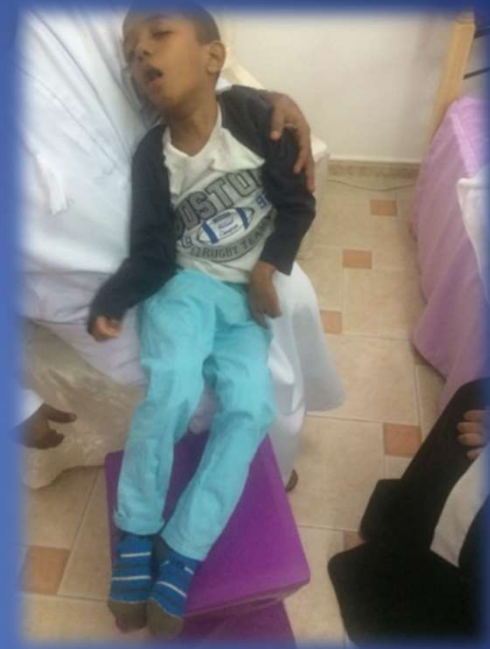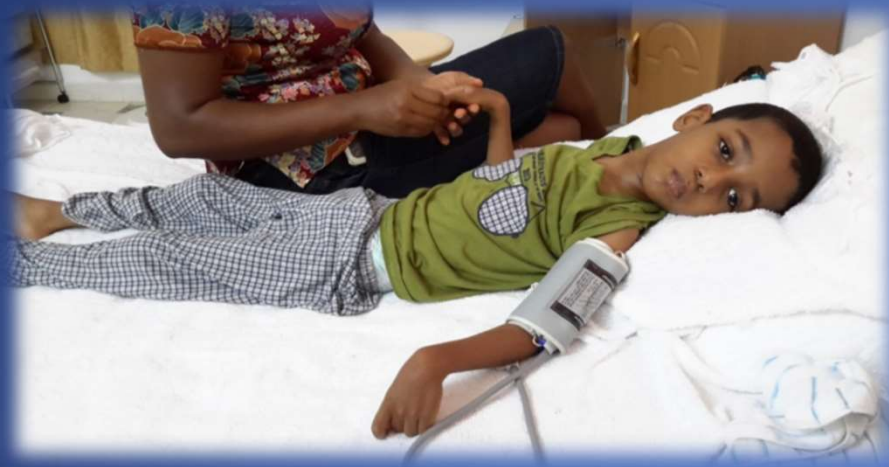Ангіомаркери судинного басейну мозку



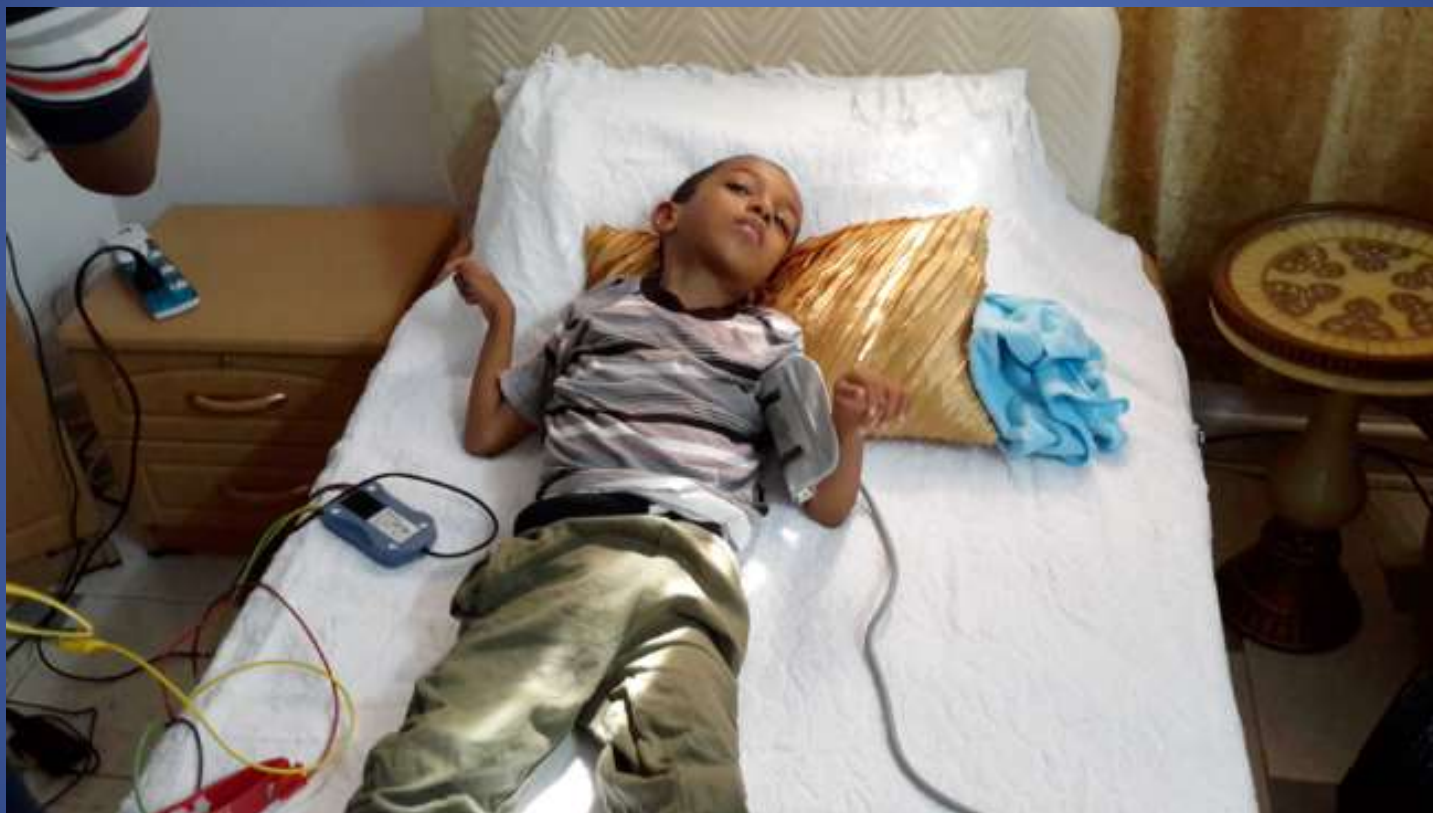1-й день лікування психоневрологічна динаміка

Consciousness	AP	Pulse	Swallowing	eyes	Cramps	Pathological synkinesis	
stupor-sopor, mainly floating doll eyes	background 103/67, after injections 123/80	background 110, after injections 87	the spontaneous, absent, forced - 1 time per 10-15 min., holding food and liquid in the mouth, swallowing of liquid is more complicated than of the food	floating doll, photo-reactions are very poorly expressed	generalized jerking of the whole body. Two days prior to the treatment beginning there was a large generalized attack, which it was even difficult to cut off in resuscitation conditions	present, by hemitype and cross, mostly right foot+left arm	
Pain sensation	CCN		Subcortical reflexes	Trunk reflexes	Abdominal reflexes	Position of the head	Emotions
absent	bilateral deficit of oculomotor, visual, bulbar group, fixed turning of the head to the left		Snout expressed+++ Marinesco-Radovici ++, s>d	cornea, nasal and ear are present	poorly expressed	fixed with turning to the left, practically couldn't hold the head in vertical position	absent
Speech	Cough reflex and swallowing		Motion sphere		Sleep	Salivation	Thermoregulation
no vocalization	cough reflex is present, swallowing is very complicated. Pseudobulbar syndrome with elements of forced laughter and weeping according to his mother		Autokinesias are absent, permanent generalized convulsive motions prevail in the extremities and in the head despite of anticonvulsant medications. At passive motions there are elements of the spastic sticking, somehow like the "rack-wheel", more expressed in the left leg.		Ordinary	expressed	hands and feet are cold

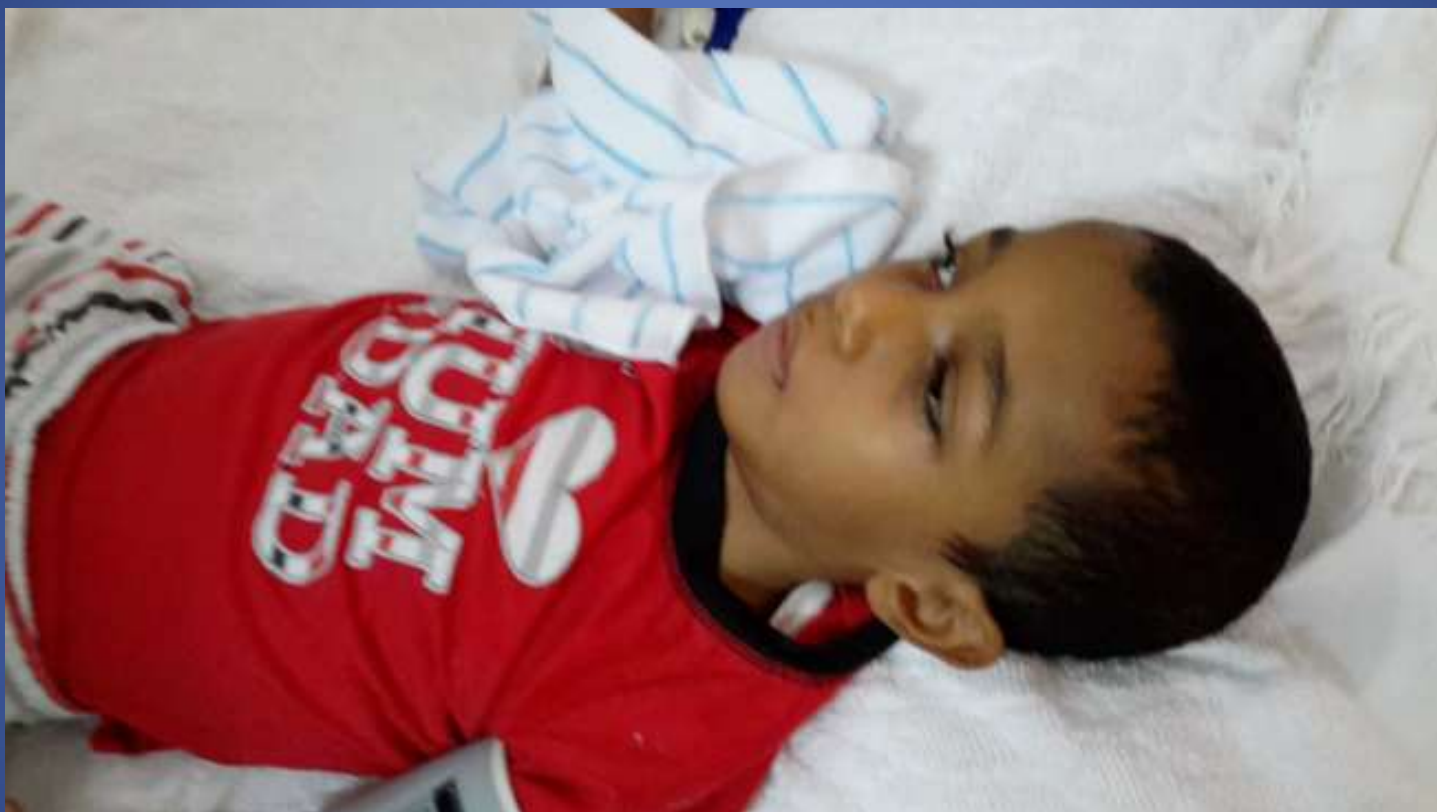1-й день лікування



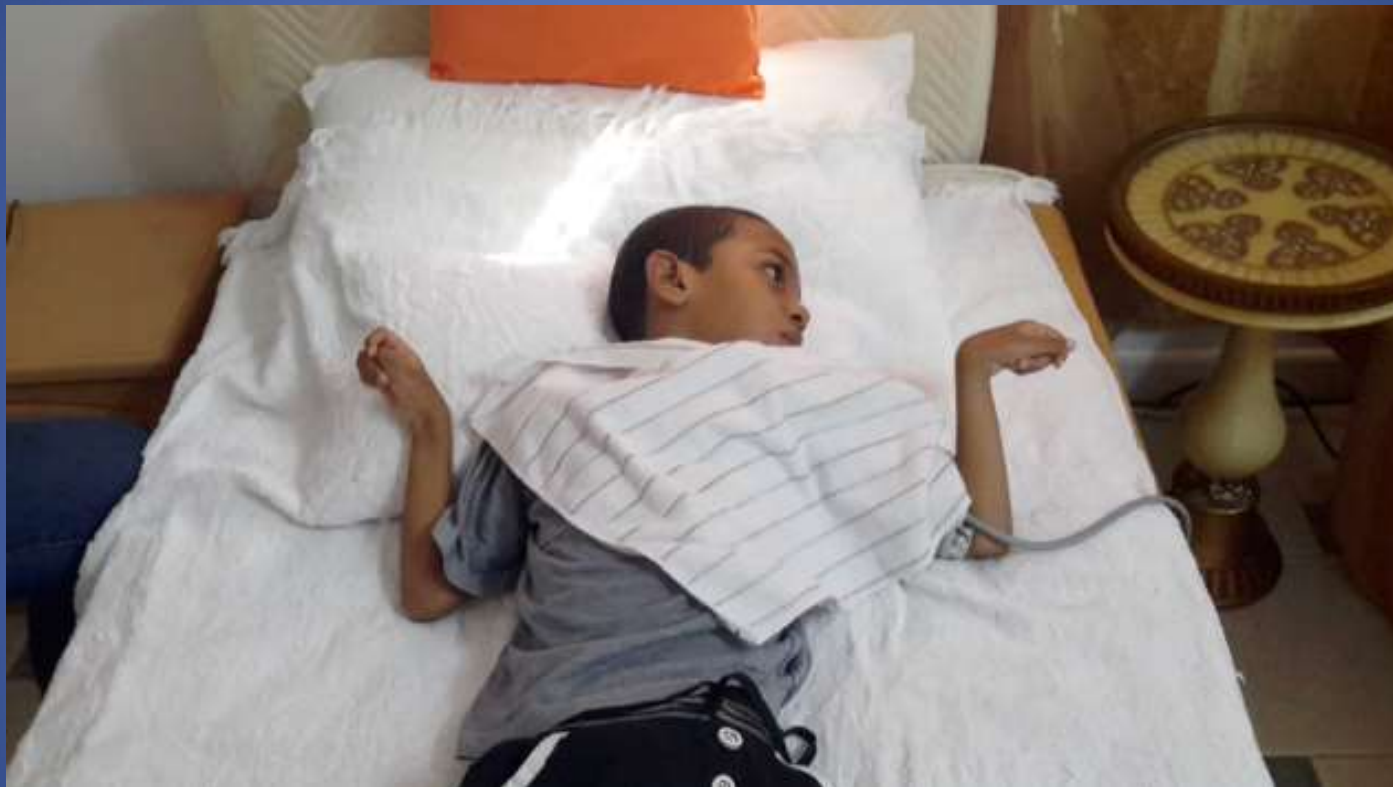1-й день



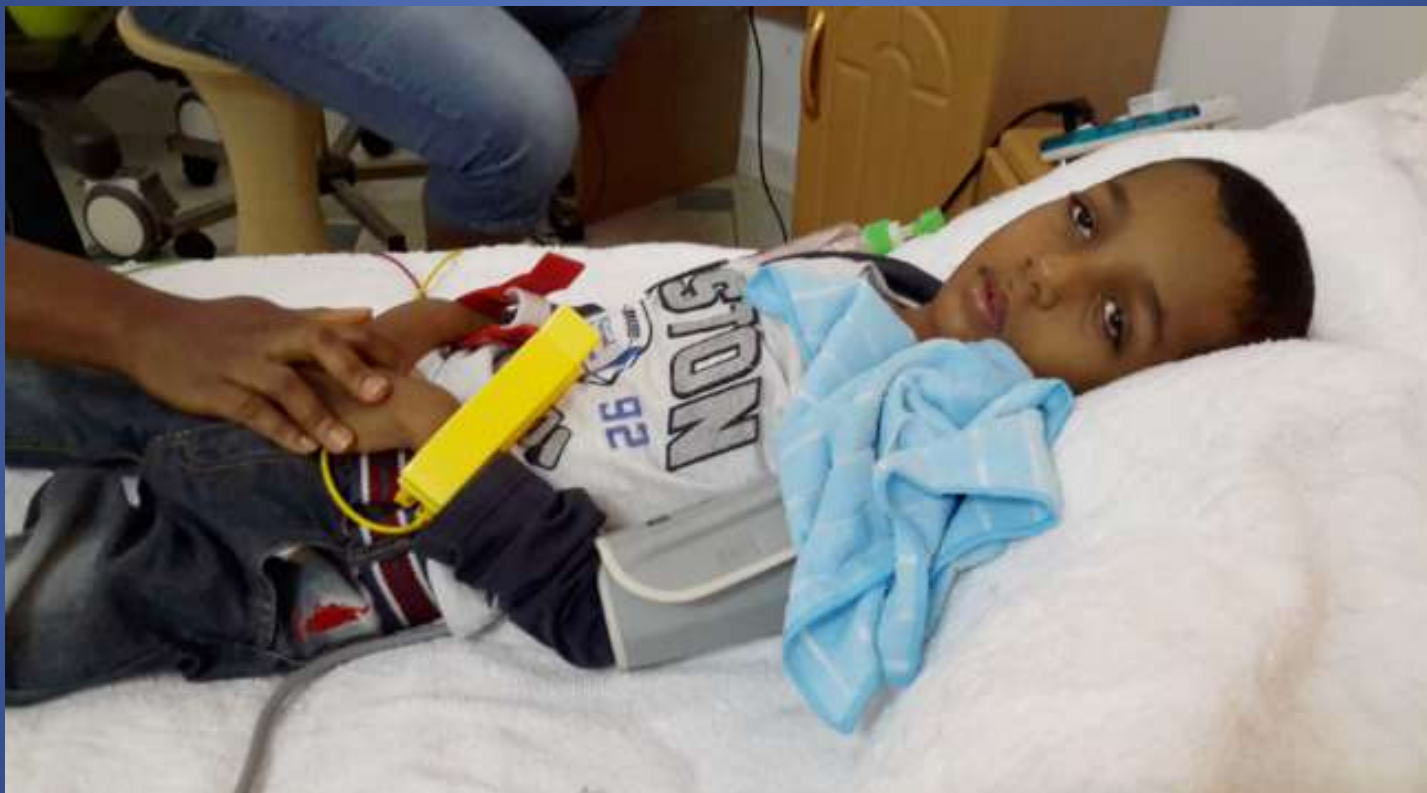2-й день



3-й день




4-й день



4-й день



5-й день лікування
Результат технології судинного скринінгу

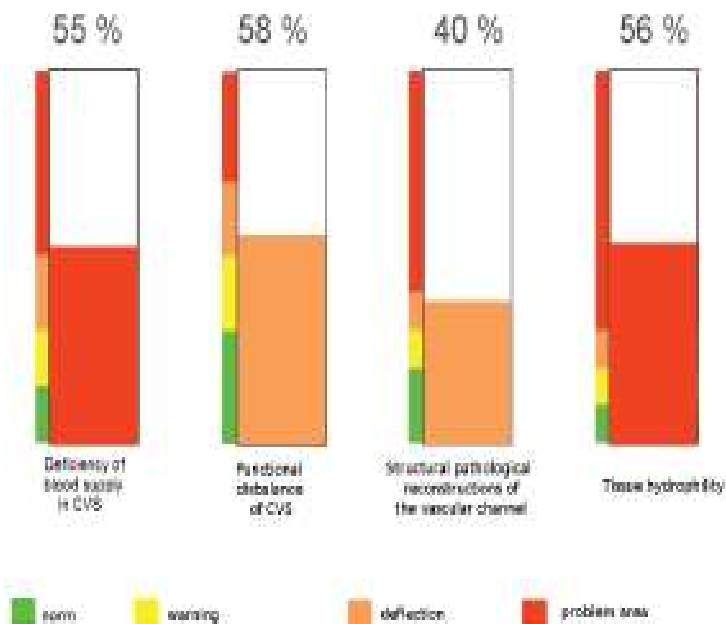


**поліпшується кровообіг за
рахунок посилення
кровообігу першого
ряду капілярів і зменшення
 набряку**

VASCULAR SCREENING TECHNOLOGY

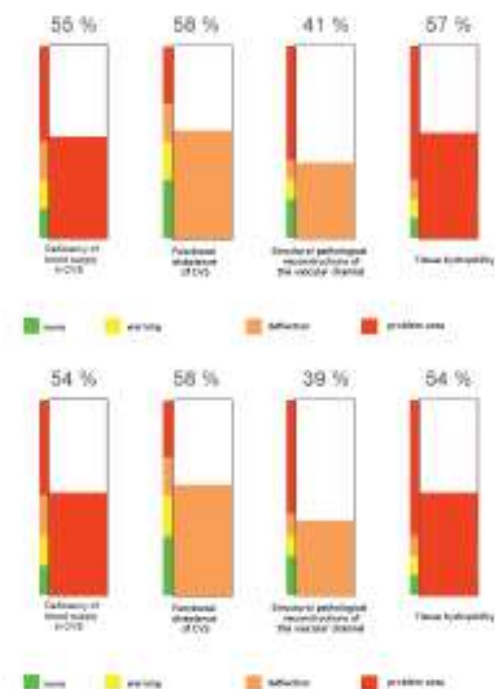
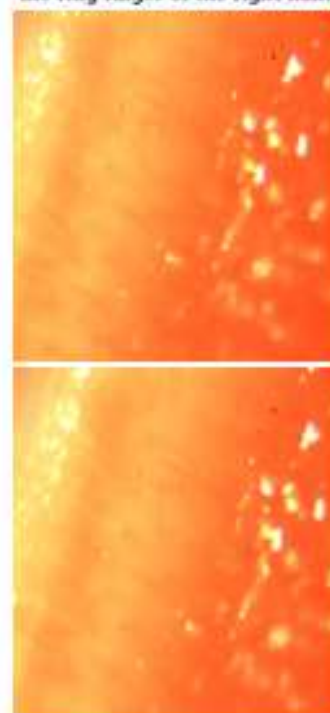
Data of check-up: 09.09.2016, 09:27	Name of a patient: Haroon Al Maskari	Date of birth of a patient: 01.01.2009
Medical card: 18	Full age: 7	Examined by: Omwuka Obinna

Загальна гісторграма судинного скринінгу, сформована на основі кількох зображень



Attention! When at least one parameter is in a red range - It is necessary immediately to start the course of vascular treatment - angiotherapy.

the ring-finger of the right hand



Conclusions of the screening of the individual adequacy of blood supply for the organism by the cardiovascular system

The critical degree of imbalance in the work of almost all parameters of the cardiovascular system with severe deficiency of blood supply for organs and systems. High risk of combined cardiovascular and vascular organ failure. The high degree of imbalance of the cardiovascular system by the chaos 3 type.

Possible risks and condition of reserves the vascular system

High risk of reanimation states !!! Reserves of compensation of the cardiovascular system are absent. Recommended total examination of the entire cardiovascular system. The risk of structural rearrangements in micro- and peripheral vessels of various origins (it is necessary to differentiate angiodystonia, endocrinopathy, pathological angiogenesis, increased blood clots, etc.).

Necessary additional examinations of the cardiovascular system

Recommended detailed further examinations of microvessels by the program of expanded vascular screening. Obligatory further examination of all vessels and the heart, kidneys to specify causal relationships of formation and development of the disease. Recommended additional examination of hormonal mirrors for sexual sphere.

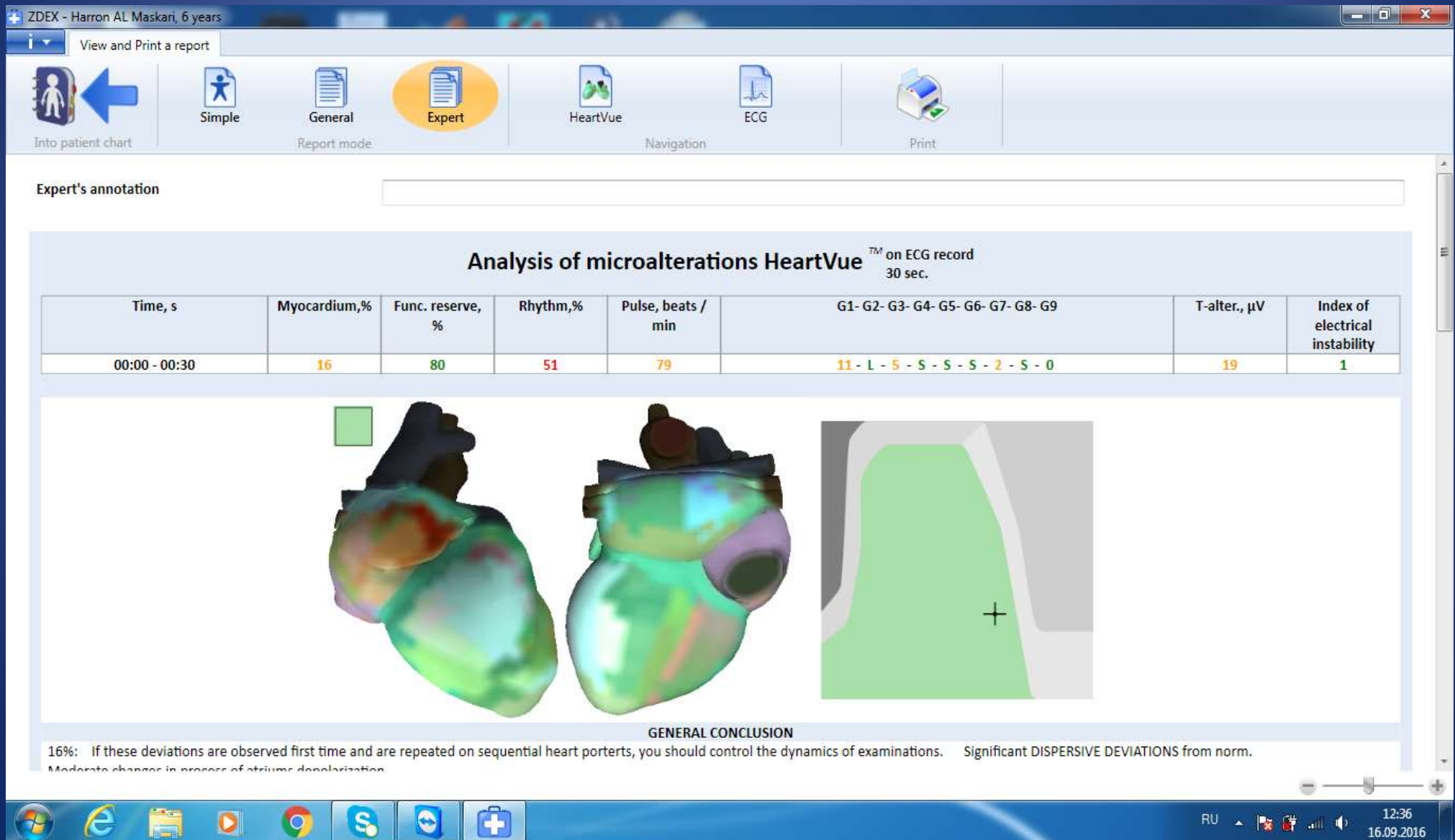
Recommendations in relation to the removal of the problem

Attention! When at least one of the parameters is in the red range, the treatment should be started immediately. Recommended urgent angiotherapy (personalized vascular treatment) to correct the cardiovascular system. The treatment process is recommended to perform only with angiomarker

5-й день лікування

Результат ЕКГ серця

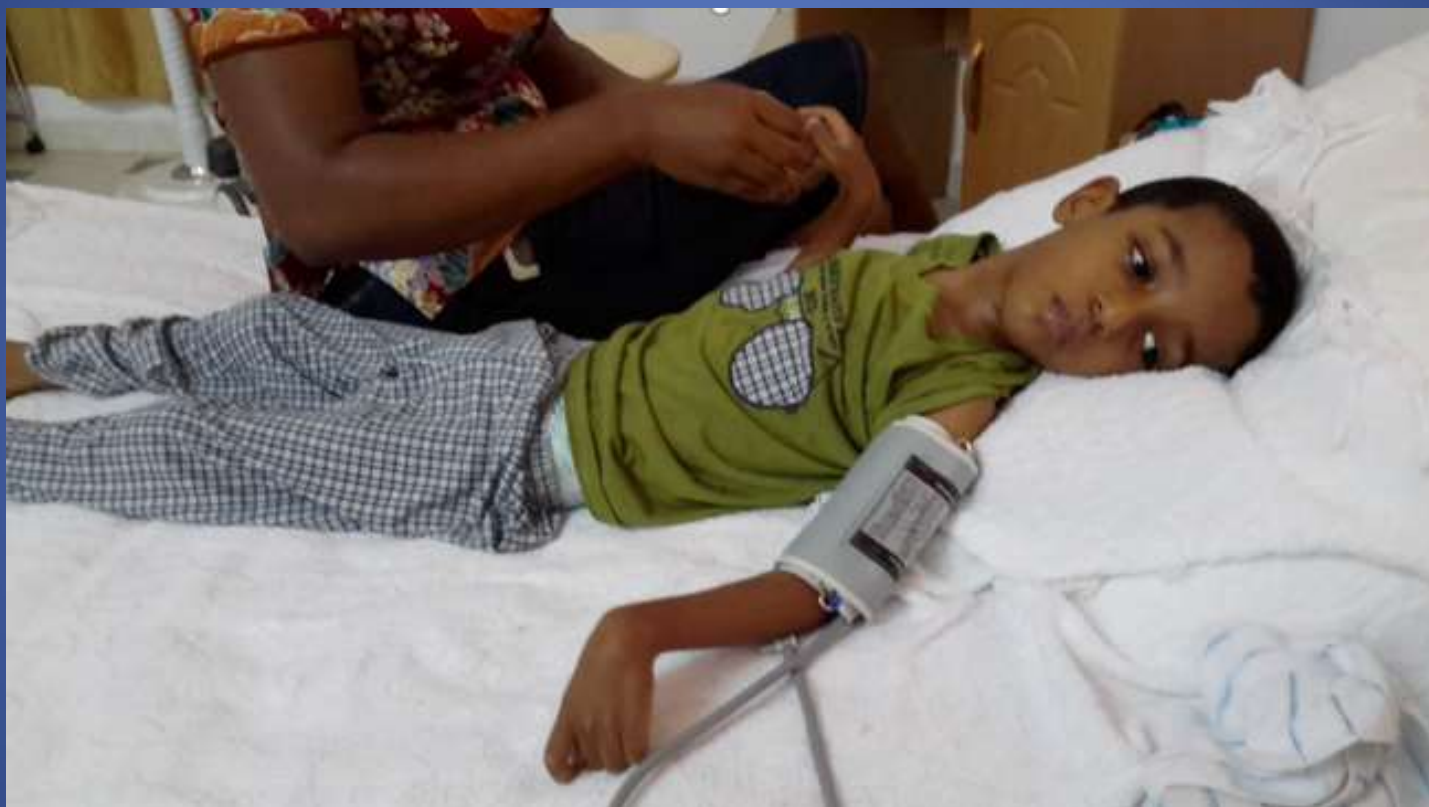Позитивна динаміка з 1-го по 5-й день лікування.



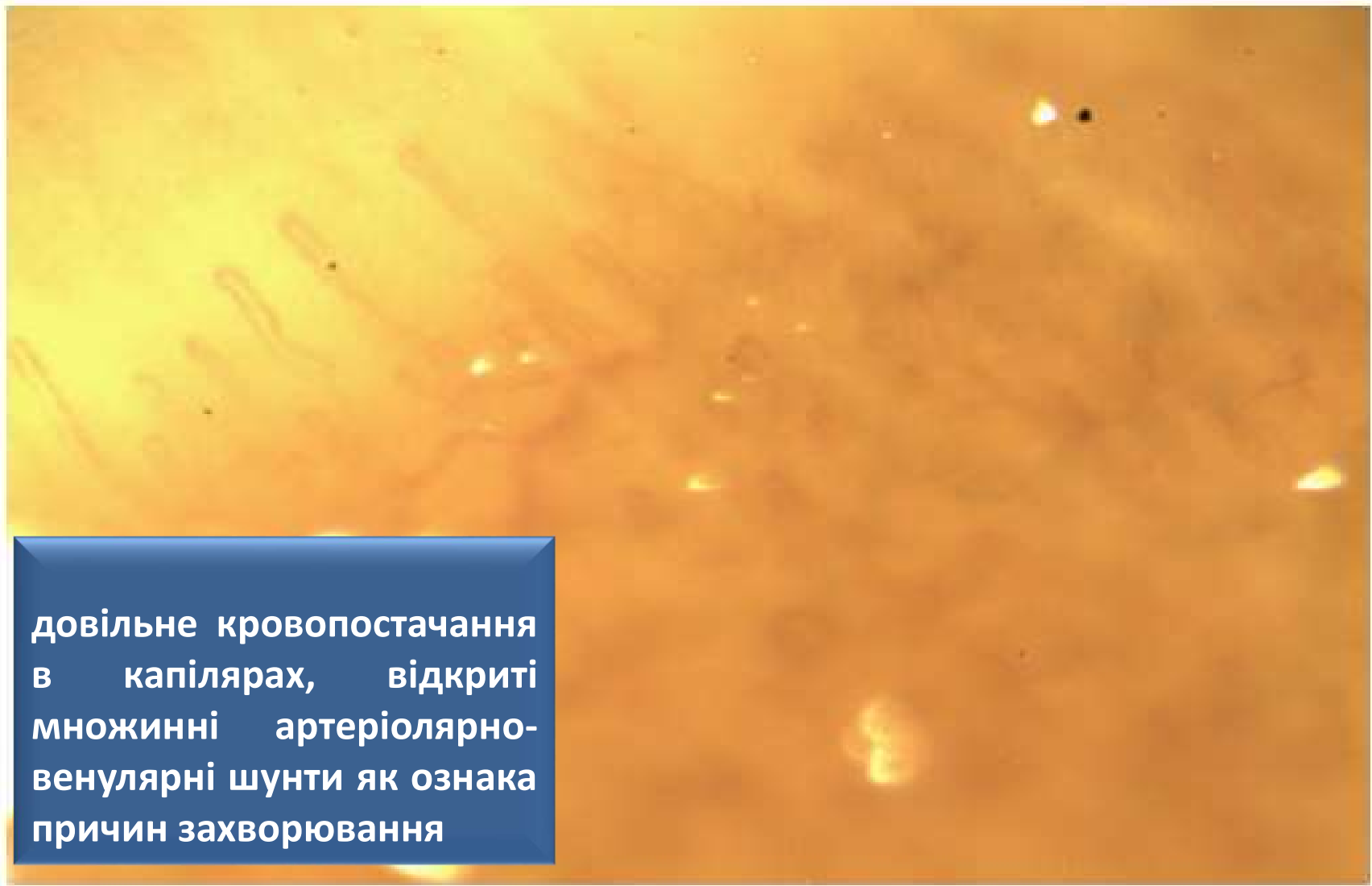5-й день лікування психоневрологічна динаміка

Swallowing		eyes	Cramps	Pathological synkinesis	Pain sensation	CCN	Subcortical reflexes		
better swallows and eats quicker		There is a brief vision, however at times there are floating eyes	practically absent as the base-line state, at active motions periodically there are clonoids in both feet by turns	no	feeling of touch and deep sense has a tendency to renewal	tries to feel taste of meal at the beginning of reception of meal	snout ++		
Trunk reflexes	Abdominal reflexes	Position of the head	Emotions	Speech	Cough reflex and swallowing	Motion sphere	Sleep	Salivation	Thermoregulation
norm	weak, exhausted quickly	retains turning of the head to the left		periodically emotionally colouring sounds, attempt insignificantly to move lips as an element of taciturn reflex communication	coughing is stored, well expressed at swallowing wrongly. Swallowing is better with an attempt to savour that given meal. Swallowing well stimulated by the by external irritants of face, by internal stimuli with the spoon of lips and tongue.	Babinskyy is less expressed, periodic spontaneous motions in knees, fingers of both hands. Next 2 days the left extremities made spontaneous motions. Elements of clonus in feet at the attempt of active motion from uncomfortable position of bended legs. Fixed turning of the head to the left, after injection - elements of motions	norm	insignificantly less expressed	warm

5-й день



*10-й день лікування.
Результат технології судинного скринінгу*

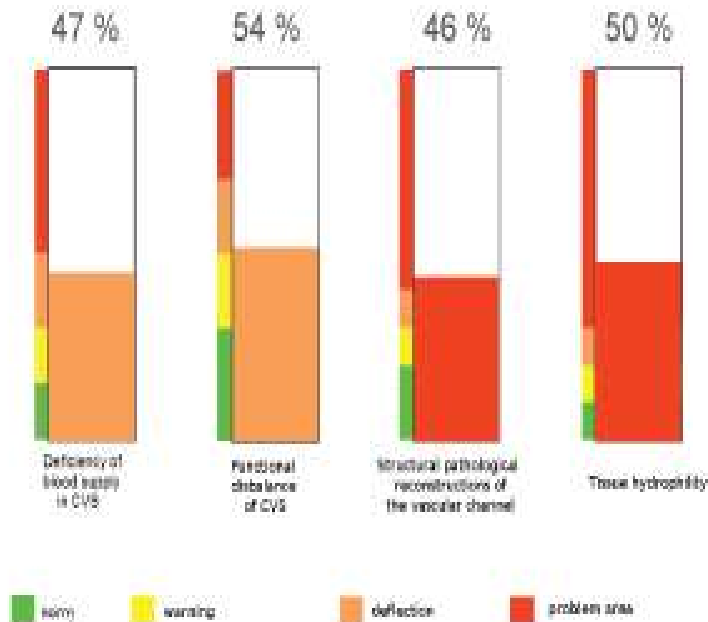


довільне кровопостачання
в капілярах, відкриті
множинні артеріолярно-
венулярні шунти як ознака
причин захворювання

VASCULAR SCREENING TECHNOLOGY

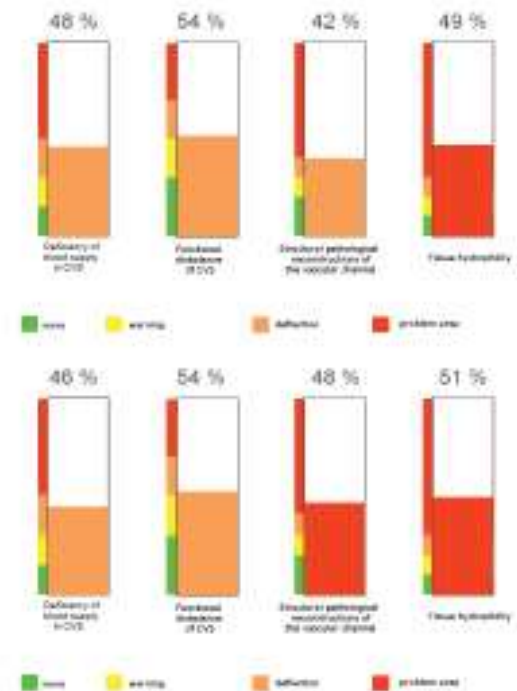
Date of check-up: 16.09.2016, 11:51	Name of a patient: Haroon Al Maskari	Date of birth of a patient: 01.01.2009
Medical card: 18	Full age: 7	Examined by: Omwuka Obinna

Загальна гісторграма судинного скринінгу, сформована на основі кількох зображень



Attention! When at least one parameter is in a red range - it is necessary immediately to start the course of vascular treatment - angiotherapy.

the ring-finger of the left hand



Conclusions of the screening of the individual adequacy of blood supply for the organism by the cardiovascular system

The high degree of imbalance of the cardiovascular system by the chaos 3 type. Subcritical reduction of all functional parameters of the cardiovascular system by 50% of the deficit from the physiological norm. Extremely alerting expressed changes in hemodynamic parameters of microvessels that at any moment can lead to critical states.

Possible risks and condition of reserves the vascular system

High risk of critical and terminal states on the background of physical and mental, psychological and emotional overload !!! Compensation reserves of the cardiovascular system are practically absent. The risk of structural rearrangements in micro- and peripheral vessels of various origins (it is necessary to differentiate angiodystonia, endocrinopathy, pathological angiogenesis, increased blood clots, etc.).

Necessary additional examinations of the cardiovascular system

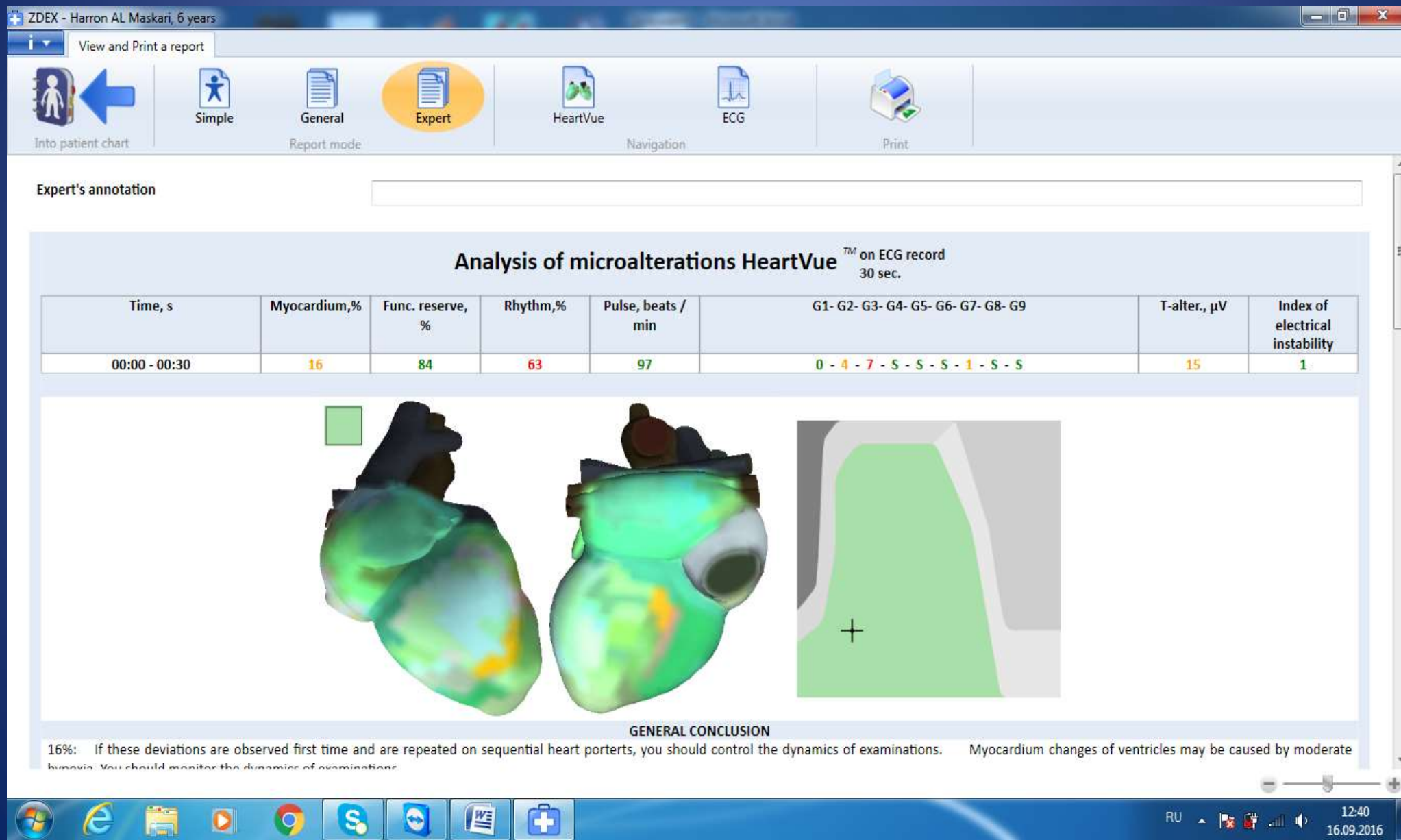
Recommended detailed examination of microvessels with expanded vascular screening program - Angiomarkers and detailed examination of the cardiovascular system. Obligatory further examination of all vessels and the heart, kidneys to specify causal relationships of formation and development of the disease. Recommended additional examination of hormonal mirrors of the sexual sphere.

Recommendations in relation to the removal of the problem

Attention! When at least one of the parameters is in the red range, the treatment should be started immediately. Recommended urgent angiotherapy (personalized vascular treatment) to correct the

10-й день лікування

Результат електрокардіограми серця



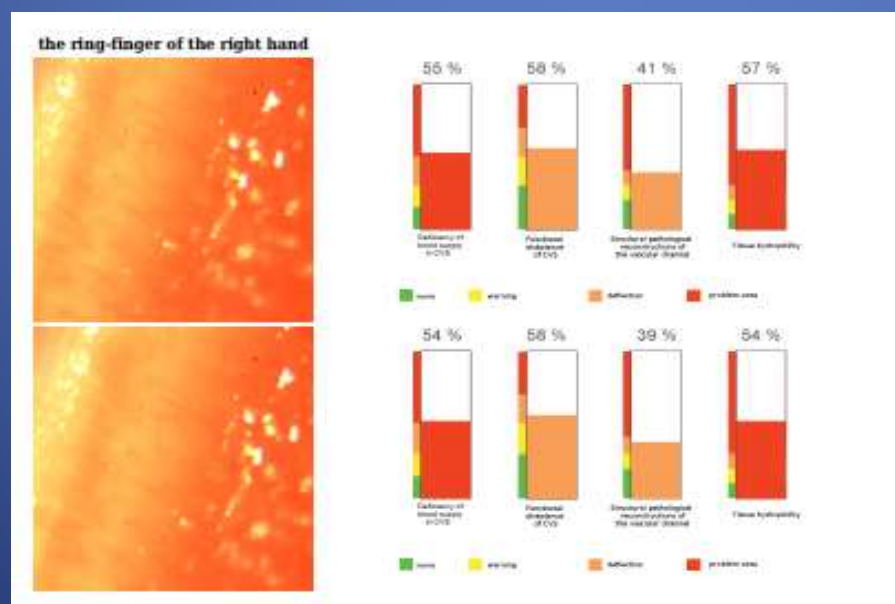
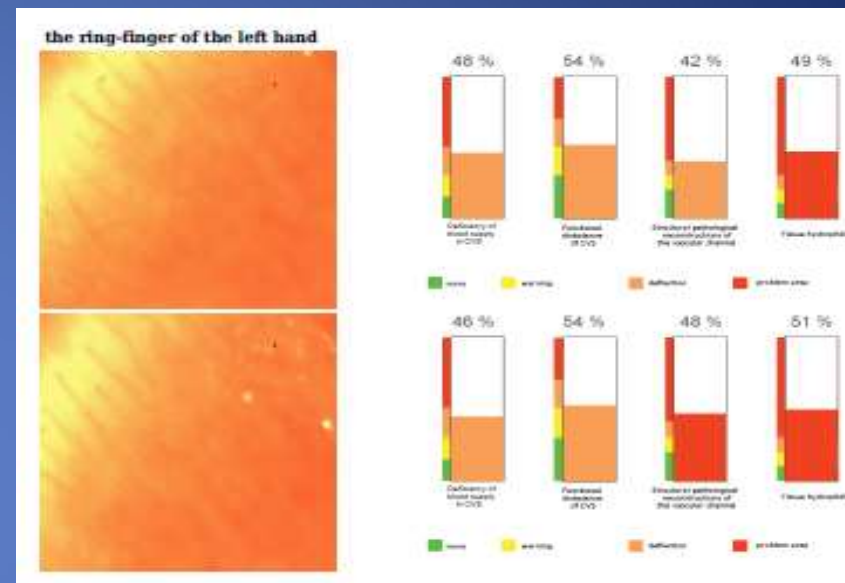
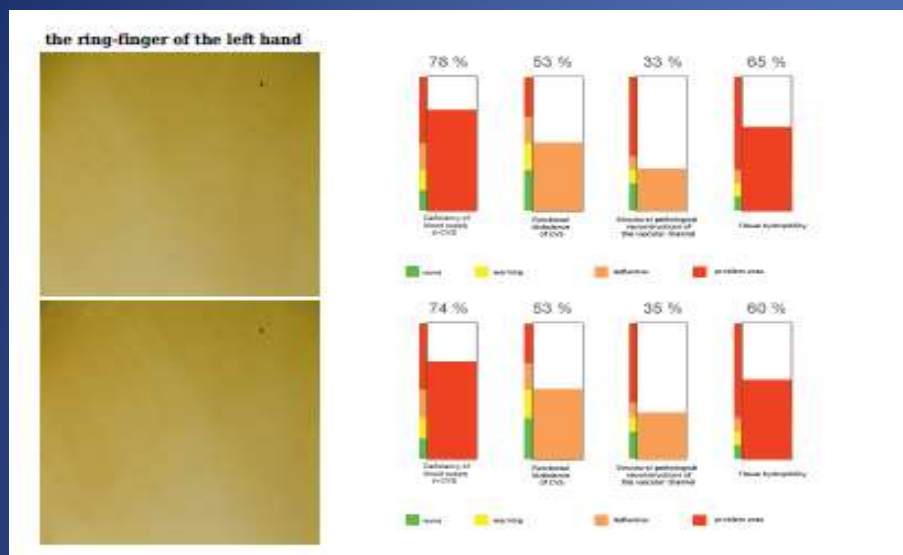
10-й день лікування психоневрологічна динаміка

Swallowing		eyes			Cramps		Pain sensation	Subcortical reflexes	
better swallows and eats on a background and at irritants		eyes are open, such impression that tries to listen to the surrounding sounds. Eye motions into sides are limited			First attempt of motion of feet as avoiding from the strong irritant of his foot the stimulated by pulling up the legs in knees to the stomach		Pathological synkinesiss	snout ++	
Trunk reflexes	Abdominal reflexes	Position of the head	Emotions	Speech	Cough reflex and swallowing	Motion sphere	Sleep	Salivation	Thermoregulation
norm	exhausted quickly, reduced	first straight	elements of attempts of smile and single simple sound of vocalisation	first clear simple single sound	coughing reflex is preserved	At first there are elements of protective motions of pulling back of the feet to an irritant - scratching of his foot	norm	considerably reduced	norm

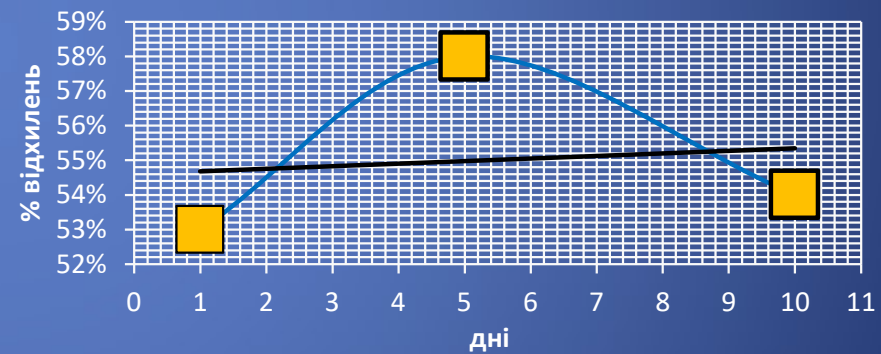
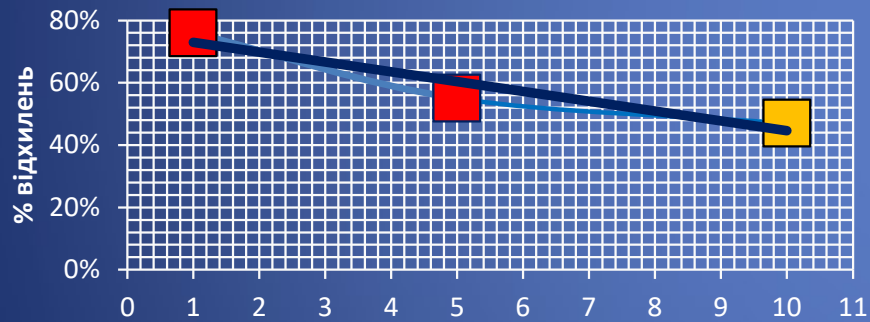
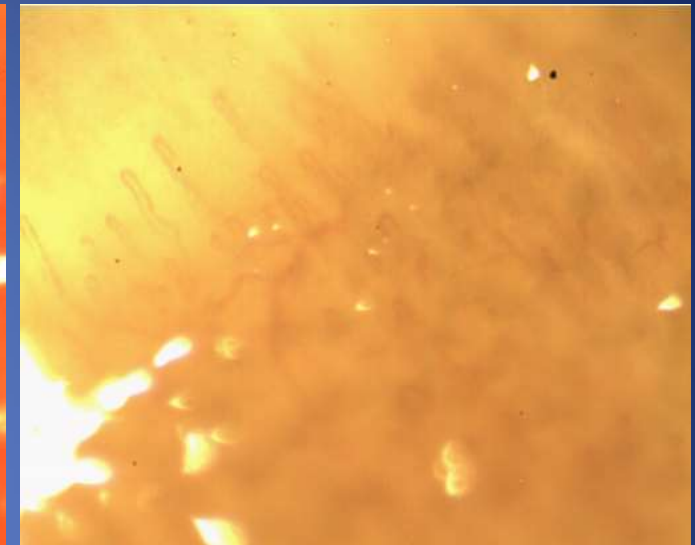

10-й день



Порівняльні гістограми 1-го, 5-го та 10-го днів лікування та обстеження

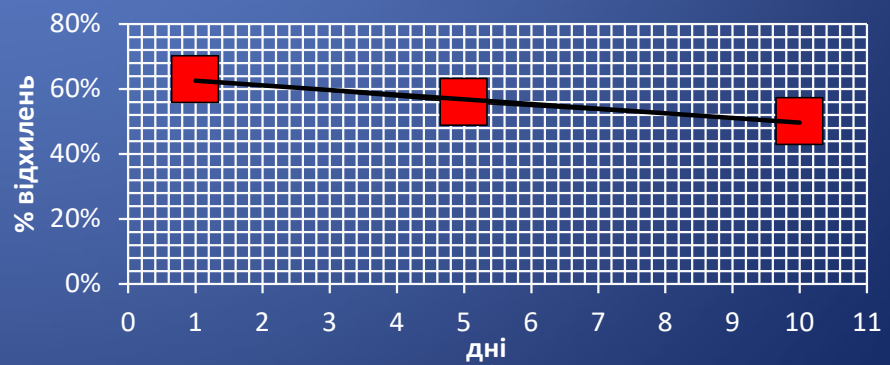
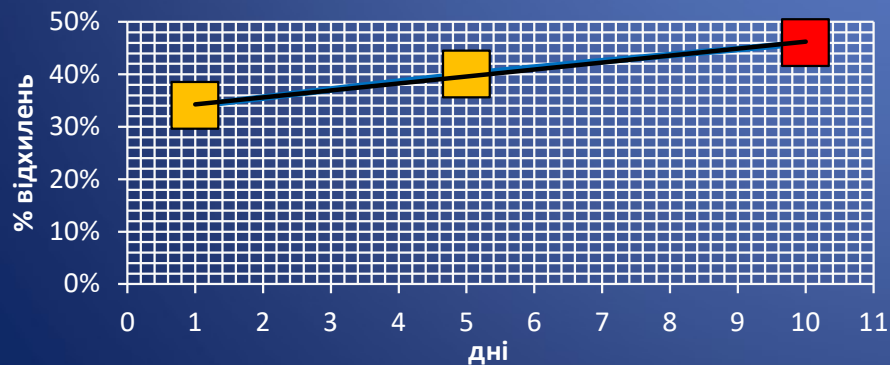


ПОРІВНЯЛЬНІ ГІСТОГРАМИ 1-ГО, 5-ГО ТА 10-ГО ДНІВ ЛІКУВАННЯ ТА ОБСТЕЖЕННЯ



Динаміка кровопостачання

Динаміка функціонального дисбалансу ССС



Динаміка структурної патології

Динаміка гідрофільності тканин

*За технологіями лікування та
нейрореабілітації акад. проф.,
д.мед.н. Уляни Лущик*